

Spontaneous Zymbal's gland tumor in a 25-week old Wistar male rat: a case report

Ana I. Faustino-Rocha, Paula A. Oliveira*, Ana M. Calado and F. Seixas



Abstract

This work describes a spontaneous Zymbal's gland tumor in a 25-week old Wistar male rat that had been included in the control sedentary group of an assay of hormone and chemically-induced prostate cancer. The animal exhibited a unilateral, round, ulcerated mass, ventral to the left ear. Histopathologically, it was a non-encapsulated mass composed of solid sheets of basaloid epithelial cells with

occasional sebocyte differentiation. Multiple cells presented variable sized eosinophilic granules. The histopathological data were compatible with a basaloid carcinoma, and its location is suggestive of Zymbal's gland (auditory sebaceous gland) origin.

Key words: *auditory sebaceous gland; chemical carcinogenesis; young rat*

Introduction

Reports describing spontaneous tumors in laboratory animals are scarce (Faustino-Rocha et al., 2017). The spontaneous development of tumors in rats is age-related, and uncommon during the first year of life (Son and Gopinath, 2004). The spontaneous tumors described in Wistar rats after the first year of life most

often originate in the pituitary and adrenal glands (Bomhard, 1992). Although rare, it is important to obtain data about the occurrence of tumors in laboratory animals during their life, as spontaneous tumors observed prior to the end of a study may induce a misinterpretation of the data (Son and Gopinath, 2004).

Ana I. FAUSTINO-ROCHA, Centre for the Research and Technology of Agro-Environmental and Biological Sciences (CITAB), Institute for Innovation, Capacity Building and Sustainability of Agri-food Production (Inov4Agro), Vila Real, Portugal, Department of Zootechnics, School of Sciences and Technology, Évora, Portugal, Comprehensive Health Research Center (CHRC), Évora, Portugal; Paula A. OLIVEIRA*, (Corresponding author, e-mail: pamo@utad.pt), Centre for the Research and Technology of Agro-Environmental and Biological Sciences (CITAB), Institute for Innovation, Capacity Building and Sustainability of Agri-food Production (Inov4Agro), Vila Real, Portugal, Department of Veterinary Sciences, School of Agrarian and Veterinary Sciences (ECAV), University of Trás-os-Montes and Alto Douro (UTAD), Vila Real, Portugal; Ana M. CALADO, Fernanda SEIXAS, Department of Veterinary Sciences, School of Agrarian and Veterinary Sciences (ECAV), University of Trás-os-Montes and Alto Douro (UTAD), Vila Real, Portugal, Animal and Veterinary Research Center (CECAV), Associate Laboratory for Animal and Veterinary Sciences (AL4Animals), Vila Real, Portugal

Case description

Animals

In total, 95 male Wistar rats of four weeks of age were acquired from Harlan Interfauna Inc. (Barcelona, Spain) for use in an assay of hormone and chemically-induced prostate cancer. Animals were handled according to the national (Decree-law 113/2013) and European legislation (European Directive 2010/63/EU) on the protection of animals used for scientific purposes. Procedures were approved by the Portuguese Ethics Committee for Animal Experimentation (*Direção Geral de Alimentação e Veterinária*, Approval no. 021326) and by the University Ethics Committee. Animals were housed at the animal facilities of the University of Trás-os-Montes and Alto Douro (UTAD) in filter-capped polycarbonate cages under controlled conditions of temperature

($23\pm 2^{\circ}\text{C}$), humidity ($50\pm 10\%$), air system filtration (10-20 ventilations/h) and on a 12/12h light/dark cycle. A basic standard laboratory diet (4RF21, Mucedola, Italy) and tap water were supplied *ad libitum*. Animals were maintained in quarantine for two weeks and were allowed to acclimatize to the animal facilities conditions for two weeks. After this, they were randomly divided into experimental groups. Each animal was observed individually and weekly to identify changes in behavior or health. At 25 weeks of age (18th week of the experiment), one animal from the control group, i.e., not subjected to the administration of any substances or manipulations, exhibited a 0.5 cm diameter, unilateral, round, firm mass ventral to the left ear, near the mandibulo-maxillary junction; after two weeks, the mass ulcerated (Figure 1). Focusing on animal welfare, it was humanely sacrificed by

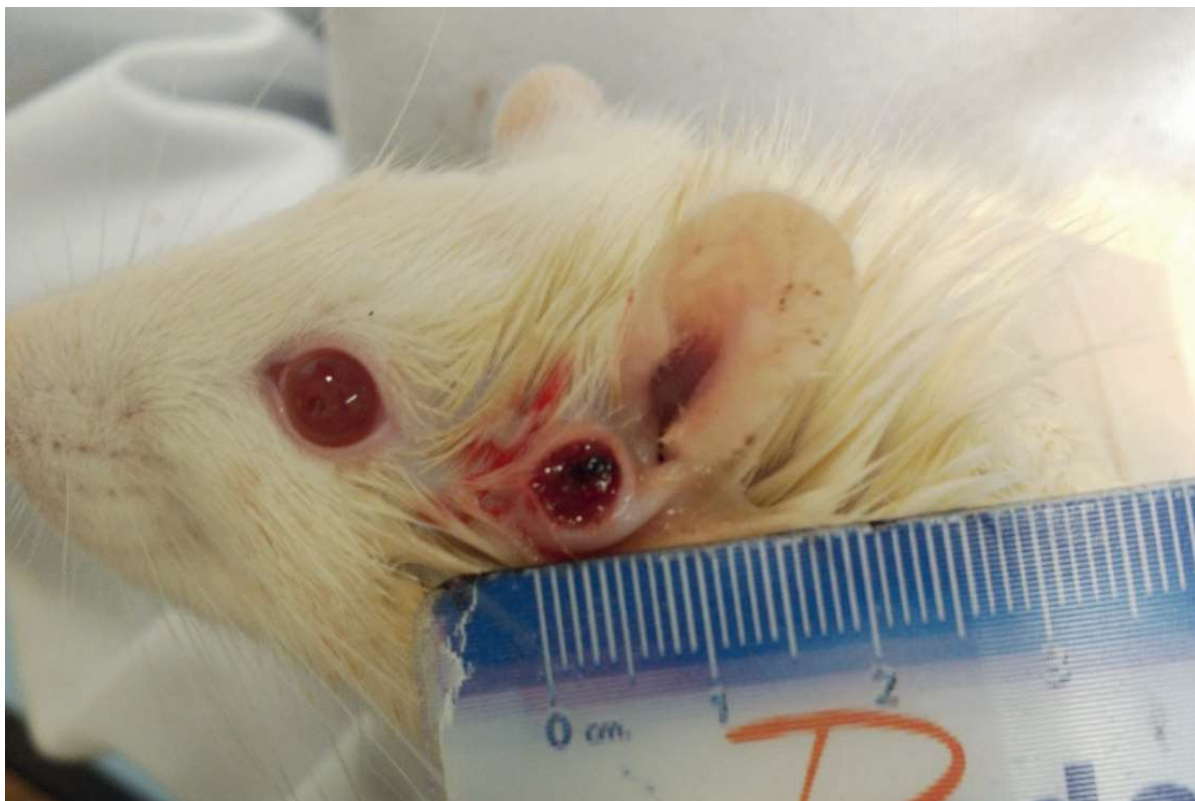

Figure 1. Macroscopic appearance of the Zymbal's gland tumor. It appeared as a 0.5 mm diameter, unilateral, round, ulcerated firm mass ventral to the left ear, at the mandibulo-maxillary junction.

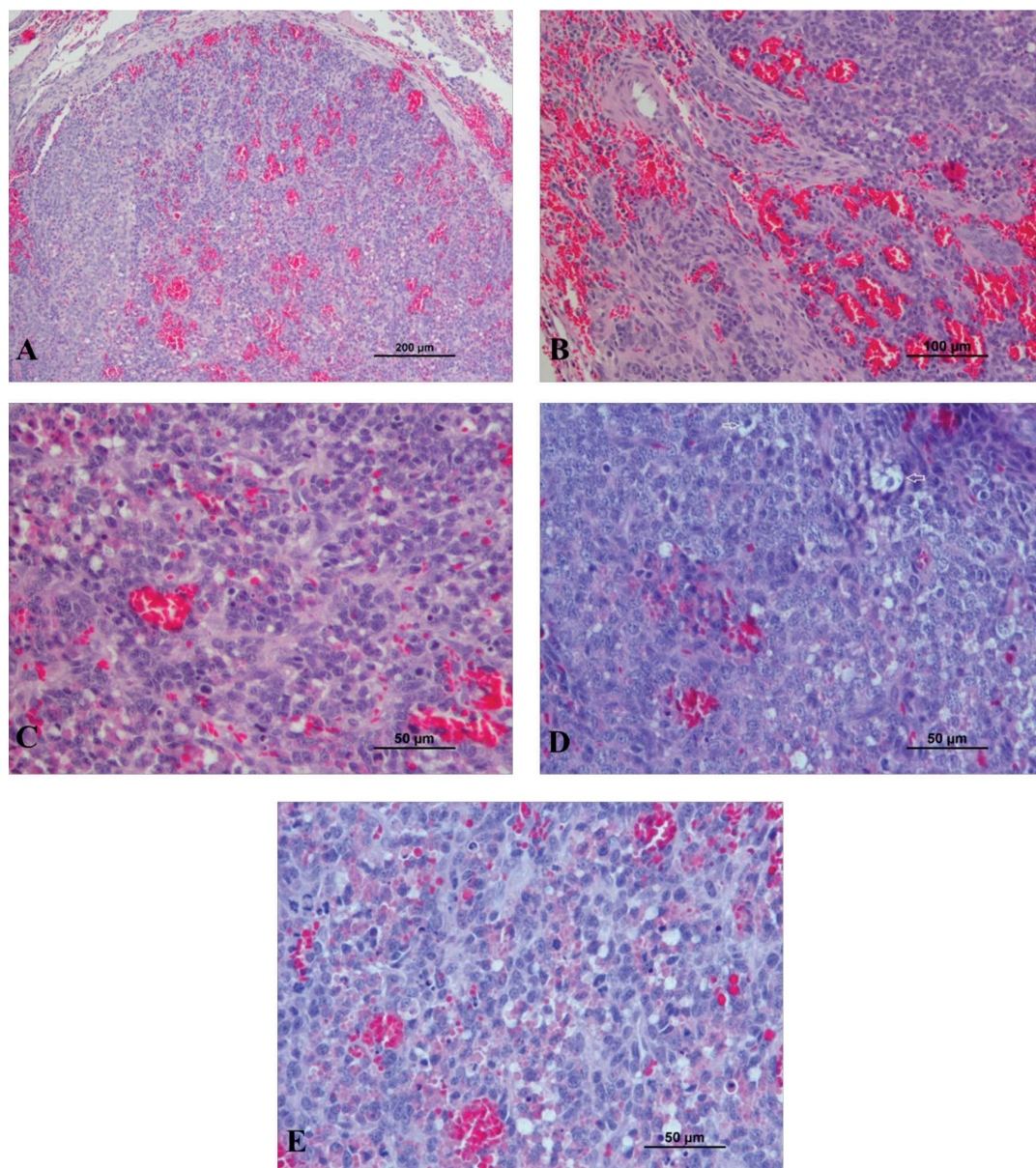


Figure 2. Microscopic appearance of the Zymbal's gland tumor. It was a non-encapsulated but circumscribed, irregular mass (A). It showed congestion, hemorrhage and focal necrosis (B and C). The mass was composed of solid sheets of cuboid basaloid to moderate size polyhedral cells. Multiple tumor cells showed intracytoplasmic vacuoles (arrows), sebocyte differentiation was seldom observed (D). Multiple cells presented variable size eosinophilic granules (D and E). Several mitosis (42 mitosis *per* 10 high power magnification were observed) (E).

intraperitoneal overdose of pentobarbital sodium (Eutasil, CEVA, Portugal). A complete necropsy was performed. The mass and all organs were collected and fixed in 10% buffered formalin for 24 h. After fixation, the mass and organs were routinely processed for histological analysis.

Microscopic examination

Three μm sections from this mass were stained with Hematoxylin and Eosin (H&E) and Periodic acid-Schiff stain (PAS). Histopathological analysis revealed a non-encapsulated but circumscribed, irregular mass composed of sol-

id sheets or cords of cuboid basaloid to moderate size, polyhedral epithelial cells. Although multiple tumor cells showed intracytoplasmic vacuoles, sebocyte differentiation was seldom observed, and cells presented variable size and number of proteinaceous eosinophilic granules, positive to PAS stain. The neoplasia presented congestion and hemorrhage, focal necrosis, areas of stromal microinvasion, and a high mitotic index (42 mitosis *per* 10 high power magnification (40x)). No embolic cells nor metastatic focus were observed in the macro and/or microscopic examination (Figure 2).

The remaining organs did not exhibit significant alterations. The tumor was classified as a microinvasive basaloid Zymbal's gland carcinoma, granular type (Mecklenburg et al., 2013).

Discussion

Wistar rats began to be used in biomedical research since 1906, when the Wistar Institute developed this strain for use as a laboratory animal (Wistar Institute, n.d.). Currently, the Wistar and Sprague-Dawley rat strains are the most used laboratory animals worldwide (Sengupta, 2013) albino rats became the most commonly used experimental animals in numerous biomedical researches, as they have been recognized as the preeminent model mammalian system. But, the precise correlation between age of laboratory rats and human is still a subject of debate. A number of studies have tried to detect these correlations in various ways, But, have not successfully provided any proper association. Thus, the current review attempts to compare rat and human age at different phases of their life. The overall findings indicate that rats grow rapidly during their childhood

and become sexually mature at about the sixth week, but attain social maturity 5-6 months later. In adulthood, every day of the animal is approximately equivalent to 34.8 human days (i.e., one rat month is comparable to three human years. Despite this, publications concerning to the occurrence of spontaneous tumors at early ages in this strains are not frequent (Faustino-Rocha et al., 2017). However, this information is crucial in understanding the number of animals needed in each experiment, since premature death due to tumors or the need to sacrifice the animals before the predicted date can endanger the success of the experiments. Two studies have been performed to evaluate spontaneous tumour development over 30 months in 900 Wistar rats (450 males and 450 females) (Bomhard, 1992) breeder: Winkelmann, Borchon and for 24 months in 2520 Wistar rats (1261 males and 1259 females) (Bomhard and Rinke, 1994) breeder: Winkelmann, Borchon. They did not observe spontaneous tumor development during the first year of life in either study. After the first year of age, a total of 1211 tumors (565 in males and 646 in females) were observed in 716 animals (333 males and 383 females) in the first study. Of these, 251 were classified as malignant tumors (100 in males and 151 in females) (Bomhard, 1992) breeder: Winkelmann, Borchon. In the second study, a total of 1485 tumors (722 in males and 763 in females) were found in 1165 rats (570 males and 595 females), of which 333 were classified as malignant (119 in males and 214 in females) (Bomhard and Rinke, 1994) breeder: Winkelmann, Borchon. The majority of spontaneous tumors observed in both studies originated in the pituitary, adrenals, thyroid gland, pancreas, liver, heart, skin, uterus, testes, mammary glands

and ovaries (Bomhard, 1992; Bomhard and Rinke, 1994) breeder: Winkelmann, Borchon. However, our experience as researchers using laboratory animals indicates that the occurrence of tumors in younger animals is a reality. such as the case of a Shwanoma in a female rat at 22 weeks (Mecklenburg et al., 2013), a spontaneous hemangiosarcoma at 7 weeks of age (Yamane et al., 2022) or a spontaneous thymic carcinosarcoma in a rat at 21 weeks of age (Kijima et al., 2021). Zymbal's gland is a multilobulated modified sebaceous gland, frequently called the auditory sebaceous gland, positioned outside the external ear canal at the base of the ear (auricular cartilage). It is responsible for the secretion cerumen into the auditory canal. This gland is not present in humans, who instead have smaller sebaceous glands in the external acoustic meatus (Treuting and Dintzis, 2012; Sundberg et al., 2012). The classic presentation for a Zymbal's gland tumor is an dome-like ulcerated nodule on the side of the face or the base of the ear, and the majority of these tumors are unilateral (Kijima et al., 2021). Although Zymbal's gland is a frequent target of chemical carcinogens, the spontaneous development of tumors in this gland is rare (Huff et al., 1991; Walsh and Poteracki, 1994; Poteracki and Walsh, 1998) comprised of nearly 1600 individual experiments having at least 10 million tissue sections that have been evaluated for toxicity and carcinogenicity. Using the current data set of 379 studies made up of 1394 experiments, we have compiled listings of chemicals having like carcinogenic target sites for each of the 34 organs or systems for which histopathology diagnoses have been recorded routinely. The most common tumor site is the liver (15% of all experiments.

Pucheu-Haston et al. (2016) described a Zymbal's gland carcinoma in a one-year old male rat, without specifying the rat strain. The animal was initially observed to have a small amount of purulent discharge in the left external ear canal and 28 days later it exhibited a small ulceration ventral to the opening of the left ear canal. After biopsy, the lesion was histopathologically classified as a poorly differentiated Zymbal's gland carcinoma. According to that previously described by Pucheu-Haston et al. (2016), the Zymbal's gland tumor may grow quickly and ulcerate, and be confused with bite wounds or abscesses. Although we initially hypothesized that the mass detected ventral to the left ear could be a bite wound or abscess secondary to another cage rat bite (rats were housed in groups of five animals per cage), it continued to grow and ulcerate, resulting in the sacrifice of the animal to ensure its welfare.

Tumours of Zymbal's gland may contain a variable number of germinative (basal or reserve) cells, that cause distortion of the normal architecture of the gland; basaloid cells are cells that are transitional in character between basal cells and mature sebaceous cells (sebocytes). Tumors of the Zymbal's gland are believed to arise from glandular acini, or ductal epithelium (Seely, 1994), thus, these carcinomas are diagnosed as a sebaceous cell subtype or squamous cell subtype. Regardless of the subtype, the two types of cells are usually mixed in varying proportions. The carcinoma often lacks normal acinar and ductal structures (Maeno et al., 2021).

In this particular tumour there are almost no acinar and ductal structures, sebaceous differentiation is scarce, and the cells are almost intirely of a basal nature and present granular change. Basaloid carcinomas from Zymbal's gland are dif-

difficult to differentiate from basal tumours of follicular origin, as most basal tumours originate from hair follicles. The same is reported for squamous cell carcinomas of Zymbal's gland that may be difficult to differentiate from squamous cell carcinomas arising from the skin (Mecklenburg et al., 2013).

The histopathological findings indicated a basaloid carcinoma with granular cell differentiation. Granular basal tumours have conspicuous granulation (Claassen et al., 2014), and have been reported previously in the skin of a 1-year-old Wistar rat by Courtney et al. (1992). Since the mass location coincides with the anatomical position of the Zymbal's gland, the data suggests a microinvasive, basaloid cell carcinoma originating from the Zymbal's gland.

In conclusion, based on the histological findings, this is the first report of a spontaneous, microinvasive, basal cell carcinoma with granular cell differentiation from the Zymbal's gland in such a young Wistar rat.

Acknowledgments

This work was supported by National Funds by the Portuguese Foundation for Science and Technology (FCT). The authors of the research unit CITAB received funding from FCT; reference of the projects UIDB/04033/2020 and LA/P/0126/2020. The authors of the research unit CECAV received funding from FCT; reference of the projects UIDB/CVT/00772/2020 and LA/P/0059/2020.

References

- BOMHARD, E. (1992): "Frequency of Spontaneous Tumors in Wistar Rats in 30-Months Studies." *Exp. Toxicol. Pathol.* 44, 381-392. 10.1016/S0940-2993(11)80171-5.
- BOMHARD, E. and M. RINKE (1994): "Frequency of Spontaneous Tumours in Wistar Rats in 2-Year Studies." *Exp. Toxicol. Pathol.* 46, 17-29. 10.1016/S0940-2993(11)80007-2.
- CLAASSEN, S, M. ROYER and W. RUSH (2014): "Granular Cell Basal Cell Carcinoma - Report of a Case and Review of the Literature." *Am. J. Dermatopathol.* 36, 121-124.
- COURTNEY, C. L., K. L. HAWKINS and M. J. GRAZIANO (1992): "Granular Basal Cell Tumor in a Wistar Rat." *Toxicol. Pathol.* 20, 122-124. 10.1177/019262339202000116.
- FAUSTINO-ROCHA, A., A. I. GAMA, P. A. OLIVEIRA, A. ALVARADO, R. FERREIRA and M. GINJA (2017): "A Spontaneous High-Grade Undifferentiated Mammary Carcinoma in a Seven-Week-Old Female Rat." *Exp. Toxicol. Pathol.* 69, 241-244. 10.1016/j.etp.2017.01.006.
- HUFF, J., J. CIRVELLO, J. HASEMAN and J. BUCHER (1991): "Chemicals Associated with Site-Specific Neoplasia in 1394 Long-Term Carcinogenesis Experiments in Laboratory Rodents." *Environmental Health Perspectives* 93 (June): pp. 247-270. <http://www.ncbi.nlm.nih.gov/pubmed/1773796>.
- KIJIMA, K., M. SUEHIRO-NARITA, S. ITO, A. SHIRAKI and A. NII (2021): "A Spontaneous Thymic Carcinosarcoma in a Young Sprague Dawley Rat." *J. Toxicol. Pathol.* 34, 235-239. 10.1293/TOX.2020-0073.
- MAENO, A., Y. SAKAMOTO, M. HOJO, Y. TADA, J. SUZUKI, A. INOMATA, T. MORIYASU, et al. (2021): "A Case of Spontaneous Zymbal's Gland Carcinoma with Lung Metastasis in an aged Fischer 344 Rat." *J. Toxicol. Pathol.* 34, 353. 10.1293/TOX.2021-0013.
- MECKLENBURG, L. D. KUSEWITT, C. KOLLY, S. TREUMANN, E. T. ADAMS, K. DIEGEL, J. YAMATE, et al. (2013): "Proliferative and Non-Proliferative Lesions of the Rat and Mouse Integument." *J. Toxicol. Pathol.* 26 (Suppl): 27S-57S. 10.1293/TOX.26.27S.
- POTERACKI, J. and K. M. WALSH (1998): "Spontaneous Neoplasms in Control Wistar Rats: A Comparison of Reviews." *Toxicol. Sci.* 45, 1-8. 10.1006/toxs.1998.2493.
- PUCHEU-HASTON, C. M., J. BRANDÃO, K. L. JONES, S. L. SEALS, T. N. TULLY, J. G. NEVAREZ and D. EVANS (2016): "Zymbal Gland (Auditory Sebaceous Gland) Carcinoma Presenting as Otitis Externa in a Pet Rat (*Rattus Norvegicus*)." *J. Exot. Pet Med.* 25, 133-138. 10.1053/j.jepm.2016.03.004. 10.1177/0192623312454242/ASSET/IMAGES/LARGE/10.1177_0192623312454242-FIG2.JPEG.
- SEELY, J. (1994): "Auditory Sebaceous Glands (Zymbal's Glands)." *Pathobiology of the Aging Rat* 2, 423-433.
- SENGUPTA, P. (2013): "The Laboratory Rat: Relating Its Age With Human's." *Int. J. Prev. Med.* 4, 624-630. <http://www.ncbi.nlm.nih.gov/pubmed/23930179>.
- SON, W. C. and C. GOPINATH (2004b): "Early Occurrence of Spontaneous Tumors in CD-1 Mice and Sprague-Dawley Rats." *Toxicol. Pathol.* 32, 371-374. 10.1080/01926230490440871.

15. SUNDBERG, J. P., L. B. NANNEY, P. FLECKMAN and L. E. KING (2012): "Skin and Adnexa." In: *Comparative Anatomy and Histology: A Mouse and Human Atlas*, edited by PM Treuting and SM Dintzis, First, pp. 433-455. USA.
16. The Wistar Institute. n.d. "The Wistar Institute: Evolution of the Wistar Institute."
17. TREUTING, P. M. and S. M. DINTZIS (2012): "Special Senses: Ear." In: *Comparative Anatomy and Histology: A Mouse and Human Atlas*, edited by PM Treuting and SM Dintzis, First, pp. 419-432. USA: Elsevier Academic Press.
18. WALSH, K. M. and J. POTERACKI (1994): "Spontaneous Neoplasms in Control Wistar Rats." *Fundam. Appl. Toxicol* 22, 65-72. <http://www.ncbi.nlm.nih.gov/pubmed/8125215>.
19. YAMANE, R. M. TANAKA and S. KANEDA (2022): "Spontaneous Hemangiosarcoma in the Spleen and Liver of a Young Rat." *J. Toxicol. Pathol.* 35, 89-93. 10.1293/TOX.2021-0042.

Spontani tumor Zymbalove žlijezde u 25 tjedana starog mužjaka Wistar štakora: prikaz slučaja

Ana I. FAUSTINO-ROCHA, Centre for the Research and Technology of Agro-Environmental and Biological Sciences (CITAB), Institute for Innovation, Capacity Building and Sustainability of Agri-food Production (Inov4Agro), Vila Real, Portugal, Department of Zootechnics, School of Sciences and Technology, Évora, Portugal, Comprehensive Health Research Center (CHRC), Évora, Portugal; Paula A. OLIVEIRA, Centre for the Research and Technology of Agro-Environmental and Biological Sciences (CITAB), Institute for Innovation, Capacity Building and Sustainability of Agri-food Production (Inov4Agro), Vila Real, Portugal, Department of Veterinary Sciences, School of Agrarian and Veterinary Sciences (ECAV), University of Trás-os-Montes and Alto Douro (UTAD), Vila Real, Portugal; Ana M. CALADO, Fernanda SEIXAS, Department of Veterinary Sciences, School of Agrarian and Veterinary Sciences (ECAV), University of Trás-os-Montes and Alto Douro (UTAD), Vila Real, Portugal, Animal and Veterinary Research Center (CECAV), Associate Laboratory for Animal and Veterinary Sciences (AL4Animals), Vila Real, Portugal

Ovaj rad opisuje spontani tumor Zymbalove žlijezde u 25 tjedana starog mužjaka wistar štakora koji je uključen u kontrolnu sedentarnu skupinu ispitivanja hormonski i kemijski induciranog raka prostate. U štakora je pronađena unilateralna, okrugla, ulcerirana masa, ventralno od lijevog uha. Patohistološki, radilo se o neinkapsuliranoj masa koja se sastojala od solidnih slojeva bazalodinih

epitelnih stanica s povremenom sebocitnom diferencijacijom. Višestruke stanice su očitovale eozinofilne granule različitih veličina. Patohistološki podatci bili su kompatibilni s bazaloidnim karcinomom, a njegova lokacija ukazuje na podrijetlo iz Zymbalove žlijezde (slušna žlijezda lojnica).

Ključne riječi: *slušna žlijezda lojnica, kemijska kancerogeneza, mladi štakor*